

AAD/ACMS/ASDSA/ASMS 2012 appropriate use criteria for Mohs micrographic surgery: A report of the American Academy of Dermatology, American College of Mohs Surgery, American Society for Dermatologic Surgery Association, and the American Society for Mohs Surgery

Ad Hoc Task Force: Suzanne M. Connolly, MD (Chair),^{a,*} Diane R. Baker, MD,^{b,†} Brett M. Coldiron, MD,^{c,†} Michael J. Fazio, MD,^{d,‡} Paul A. Storrs, MD,^{e,///} Allison T. Vidimos, RPh, MD,^{f,†} Mark J. Zalla, MD,^{c,g,*,§} Jerry D. Brewer, MD,^h Wendy Smith Begolka, MBSⁱ

Ratings Panel: Timothy G. Berger, MD,^{i,†} Michael Bigby, MD,^{k,†} Jean L. Bolognia, MD,^{l,†} David G. Brodland, MD,^{m,‡} Scott Collins, MD,^{n,§} Terrence A. Cronin, Jr, MD,^{o,///} Mark V. Dahl, MD,^{a,†} Jane M. Grant-Kels, MD,^{p,†} C. William Hanke, MD,^{q,‡} George J. Hruza, MD,^{r,§} William D. James, MD,^{s,†} Clifford Warren Lober, MD, JD,^{t,///} Elizabeth I. McBurney, MD,^{u,†} Scott A. Norton, MD, MPH,^{v,†} Randall K. Roenigk, MD,^{h,†} Ronald G. Wheeland, MD,^{w,†} and Oliver J. Wisco, DO^{x,†}

Scottsdale and Tucson, Arizona; Lake Oswego and Tigard, Oregon; Cincinnati and Cleveland, Ohio; Sacramento and San Francisco, California; Palos Heights and Schaumburg, Illinois; Florence, Kentucky; Rochester, Minnesota; Boston, Massachusetts; New Haven and Farmington, Connecticut; Pittsburgh and Philadelphia, Pennsylvania; Miami and Tampa, Florida; Indianapolis, Indiana; Chesterfield, Missouri; New Orleans, Louisiana; Washington, District of Columbia; and Biloxi, Mississippi

The appropriate use criteria process synthesizes evidence-based medicine, clinical practice experience, and expert judgment. The American Academy of Dermatology in collaboration with the American College of Mohs Surgery, the American Society for Dermatologic Surgery Association, and the American Society for Mohs Surgery has developed appropriate use criteria for 270 scenarios for which Mohs micrographic surgery (MMS) is frequently considered based on tumor and patient characteristics. This document reflects the rating of appropriateness of MMS for each of these clinical scenarios by a ratings panel in a process based on the appropriateness method developed by the RAND Corp (Santa Monica, CA)/University of California—Los Angeles (RAND/UCLA).

At the conclusion of the rating process, consensus was reached for all 270 (100%) scenarios by the Ratings Panel, with 200 (74.07%) deemed as appropriate, 24 (8.89%) as uncertain, and 46 (17.04%) as inappropriate. For the 69 basal cell carcinoma scenarios, 53 were deemed appropriate, 6 uncertain, and 10 inappropriate. For the 143 squamous cell carcinoma scenarios, 102 were deemed appropriate, 7 uncertain, and 34 inappropriate. For the 12 lentigo maligna and melanoma in situ scenarios, 10 were

From the Department of Dermatology, Mayo Clinic, Scottsdale^a and Rochester^b; Baker Asthma, Allergy, and Dermatology, Lake Oswego^b; Department of Dermatology, University of Cincinnati College of Medicine^c; Skin Cancer Surgery Center, Sacramento^d; Dermatology Associates of Illinois, Palos Heights^e; Department of Dermatology, Cleveland Clinic Foundation^f; Dermatology Associates of Northern Kentucky^g; American Academy of Dermatology, Schaumburgⁱ; Department of Dermatology, University of California—San Francisco^j; Department of Dermatology, Beth Israel Deaconess Medical Center, Boston^k; Department of Dermatology, Yale University School of Medicine, New Haven^l; Zitelli and Brodland, Pittsburgh^m; Department of Dermatology, Oregon Health and Science University, Tigardⁿ; Department of Dermatology and Cutaneous Surgery, University of Miami School of Medicine^o; Department of Dermatology, University of Connecticut Health Center,

Farmington^p; Saint Vincent Hospital, Indianapolis^q; Laser and Dermatologic Surgery Center, Chesterfield^r; Department of Dermatology, University of Pennsylvania Systems, Philadelphia^s; Department of Dermatology and Cutaneous Surgery, University of South Florida, Tampa^t; Department of Dermatology, Louisiana State University Health Sciences Center and Tulane University School of Medicine^u; Dermatology Division, Georgetown University Medical Center, Washington^v; private practice, Tucson^w; and 81st Medical Group, Keesler Medical Center, Keesler Air Force Base, Biloxi.^x

*Ad Hoc Task Force liaison to Ratings Panel.

[†]Official American Academy of Dermatology representative.

[‡]Official American College of Mohs Surgery representative.

[§]Official American Society for Dermatologic Surgery Association representative.

^{///}Official American Society for Mohs Surgery representative.

deemed appropriate, 2 uncertain, and 0 inappropriate. For the 46 rare cutaneous malignancies scenarios, 35 were deemed appropriate, 9 uncertain, and 2 inappropriate.

These appropriate use criteria have the potential to impact health care delivery, reimbursement policy, and physician decision making on patient selection for MMS, and aim to optimize the use of MMS for scenarios in which the expected clinical benefit is anticipated to be the greatest. In addition, recognition of those scenarios rated as uncertain facilitates an understanding of areas that would benefit from further research. Each clinical scenario identified in this document is crafted for the average patient and not the exception. Thus, the ultimate decision regarding the appropriateness of MMS should be determined by the expertise and clinical experience of the physician. (J Am Acad Dermatol 10.1016/j.jaad.2012.06.009.)

Key words: appropriate use criteria; dermatology; lentigo maligna; melanoma in situ; Mohs micrographic surgery; nonmelanoma skin cancer.

DISCLAIMER

These appropriate use criteria are intended to guide clinical decision making regarding dermatologic treatment. Generally, the complexity and severity of a patient's clinical condition should dictate the selection of appropriate dermatologic procedures or treatments. The availability of equipment or personnel may influence the selection of appropriate diagnostic or therapeutic procedures or treatments. Adherence to these criteria will not ensure successful treatment in every situation. Furthermore, these criteria should not be interpreted as setting a standard of care, or be deemed inclusive of all proper methods of care nor exclusive of other methods of care reasonably directed to obtaining the same results, even for those indications scored as inappropriate. The ultimate judgment regarding the propriety of any specific diagnostic or therapeutic treatment must be made by the physician and the patient in light of all the circumstances presented by the individual patient, and the known variability and biological behavior of the presenting disease. These criteria reflect the best available data and expert judgment at the time of development. The results of future studies may require revisions to these criteria to reflect new data and patient scenarios.

INTRODUCTION

This report addresses the appropriate use of Mohs micrographic surgery (MMS) in the treatment of cutaneous neoplasms. In the United States in 2006,

Abbreviations used:

| | |
|------------|------------------------------------------------------------------------|
| AAD: | American Academy of Dermatology |
| AHTF: | Ad Hoc Task Force |
| AUC: | appropriate use criteria |
| BCC: | basal cell carcinoma |
| KA: | keratoacanthoma |
| LM: | lentigo maligna |
| MCC: | Merkel cell carcinoma |
| MMS: | Mohs micrographic surgery |
| NCCN: | National Comprehensive Cancer Network |
| RAND/UCLA: | RAND Corp (Santa Monica, CA)/ University of California, Los Angeles |
| RP: | ratings panel |
| SCC: | squamous cell carcinoma |

there were an estimated 3.5 million nonmelanoma skin cancers diagnosed, and it is projected that there will be nearly 4 million new cases of nonmelanoma skin cancer diagnosed in the United States each year.¹ Similarly, the incidence of melanoma in situ continues to increase with an estimated 55,560 to be newly diagnosed in 2012,² with many of these likely to be of the lentigo maligna (LM) subtype.³

Because of this epidemic of skin cancer and an increase in the number of dermatologists trained in MMS, the use of this treatment modality has expanded significantly in recent years. In fact, the use of MMS increased by 400% from 1995 to 2009, and currently 1 in 4 skin cancers is being treated with MMS.⁴ As the incidence of skin cancer continues to climb and the

Funding sources: None.

Disclosure: Dr Brewer received grants from the Dermatology Foundation. Dr Bolognia served as an editor for Elsevier receiving other financial benefits. Dr Collins served on the Board of Directors for the Oregon Dermatology Society receiving no compensation. Dr Wheeland served as a consultant for Tria receiving grants. Drs Connolly, Baker, Coldiron, Fazio, Storrs, Vidimos, Zalla, Berger, Bigby, Brodland, Cronin, Dahl, Grant-Kels, Hanke, Hruza, James, Lober, McBurney, Norton, Roenigk, and Wisco, and Ms Smith Begolka have no conflicts of interest to declare.

Accepted for publication June 12, 2012.

Reprint requests: Wendy Smith Begolka, MBS, American Academy of Dermatology, 930 E Woodfield Rd, Schaumburg, IL 60173.
E-mail: wsmithbegolka@aad.org.

Published online ●●●.

0190-9622/\$36.00

© 2012 by the American Academy of Dermatology, Inc. and the American Society for Dermatologic Surgery.

<http://dx.doi.org/10.1016/j.jaad.2012.06.009>

field of MMS continues to advance, dermatologists, primary care providers, Mohs surgeons, and the health care community in general will need to understand how to best use MMS in the treatment of skin cancer.

This appropriate use criteria (AUC) document from the American Academy of Dermatology (AAD), American College of Mohs Surgery, American Society for Dermatologic Surgery Association, and American Society for Mohs Surgery reflects an ongoing effort to systematically review and categorize the appropriate use of MMS. This publication is not a comparative document of different modalities used to treat cutaneous malignancy, but a document that pertains solely to the use of MMS and the appropriateness of MMS in certain clinical scenarios. It is thus important to understand the background and scope of this publication before interpreting the rating tables.

METHODS

Evidence review

The development of this document was supported by an evidence review and analysis of surgical and disease outcomes related to the practice of MMS within the United States. The following additional search limitations were placed on the evidence review:

Search years: 1940 to 2011 (with corrections for overlapping study populations)

- Case series of $n \geq 3$ included.
- Case reports included if no other evidence available.
- Data from *Chemosurgery: Microscopically Controlled Surgery for Skin Cancer*,⁵ by Frederick E. Mohs, MD, have been included with correction for duplicative information from journal publications.

In total, 161 primary articles were identified and analyzed for the development of the supporting evidence tables for the MMS AUC: 53 for basal cell carcinoma (BCC),⁶⁻⁵⁸ 63 for squamous cell carcinoma (SCC),^{6,8-10,13,15,16,18-21,23,24,29,36,39-42,45,46,48,49,54,58-96} 23 for LM and melanoma in situ,^{10,41,97-117} 20 for dermatofibrosarcoma protuberans,^{91,103,118-135} 10 for microcystic adnexal carcinoma,^{91,136-144} 9 for atypical fibroxanthoma and malignant fibrous histiocytoma,^{10,125,145-151} 8 for Merkel cell carcinoma (MCC),^{91,152-158} 8 for leiomyosarcoma,^{14,62,125,159-162} 7 for sebaceous carcinoma,^{91,163-168} 5 for extramammary Paget disease,^{91,169-172} 10 for eccrine/mucinous carcinoma,^{10,173-181} and 7 for desmoplastic trichoepithelioma and angiosarcoma.^{10,103,182-186} In the majority of publications, more than 1 neoplasm was reported per study.

Development of clinical indications

The indications included in this document cover a wide array of dermatologic tumor and patient

characteristics encompassing the scenarios most often encountered in the contemporary clinical setting. The developed indications are not intended to be a comprehensive roster of the scenarios for which MMS could be considered, but are intended to represent approximately 85% of anticipated clinical scenarios. Although the majority of the indications in this document involve malignant neoplasms, certain benign neoplasms were also included because of their potential for locally aggressive and destructive growth, in spite of their inability to metastasize. In addition, although the Ad Hoc Task Force (AHTF) initially considered including invasive melanoma in the rating, because of the complexity of the issue, the AHTF unanimously concluded that it not be included in these AUC.

In developing the clinical indications and supporting information for this document, the 2011 National Comprehensive Cancer Network (NCCN) clinical guidelines on nonmelanoma skin cancer,¹⁸⁷ the 2011 updates to the American Joint Committee on Cancer staging system for SCC,¹⁸⁸ the 15 current Medicare carrier local coverage determination policies,¹⁸⁹ the 1995 AAD clinical practice guidelines for MMS,¹⁹⁰ and the available literature defined by the evidence review were taken into consideration.

The indications were initially developed by members of the AHTF; modified after independent review by indication reviewers, a group composed of 44 prominent dermatologists from across the country and representatives from 2 Medicare carrier organizations; and finalized after in-person clarification and refinements by the Ratings Panel (RP) with AHTF final approval. Thus 70 experts reviewed and approved these scenarios. **Fig 1** illustrates the multiple layers of the MMS AUC development process. **[F1-4/C]**

Rating process

The AUC process combines evidence-based medicine, clinical practice experience, and expert judgment by engaging a RP in a modified Delphi exercise based on the validated appropriateness method of RAND/UCLA, with the incorporation of modifications developed by the American College of Cardiology (consideration of cost) and the American College of Radiology (consensus-based ratings determination).¹⁹¹⁻¹⁹³ The 17-member panel was composed of 8 Mohs surgeons and 9 non-Mohs dermatologists representing various regions of the country, practice settings, and specialty interests. This was done to increase the breadth of panel experience and to minimize bias.

Successive rounds (3 rounds total) of individual scoring before and after a face-to-face meeting (post-round 1) and conference-call discussions (post-round

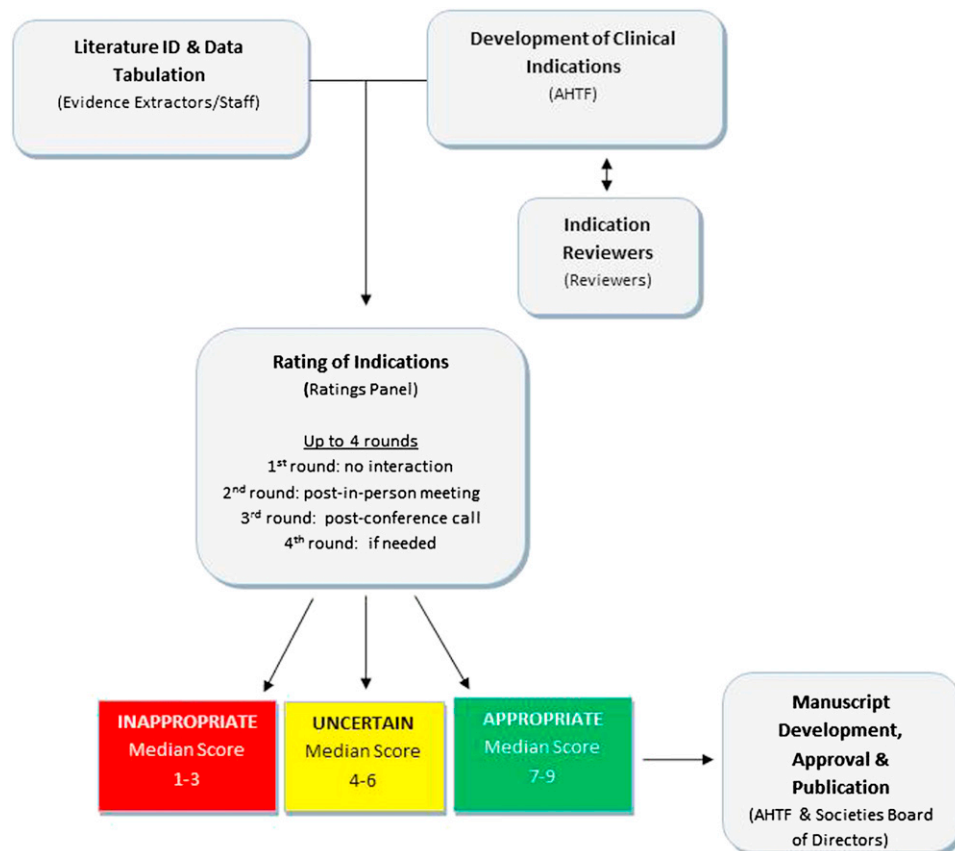


Fig 1. Mohs micrographic surgery (MMS) appropriate use criteria (AUC) development process overview. MMS AUC methodology indicating role of Ad Hoc Task Force (AHTF), Ratings Panel, indication reviewers, evidence extractors, and American Academy of Dermatology Staff during AUC development. Also indicated is flow of information to determine final appropriate use ratings and attain participating society approval.

2) by the panelists allowed opportunity for all interpretations of evidence and clinical viewpoints to be exchanged, with the goal to achieve ratings consensus where possible. RP members were provided the evidence review tables and all current US guidelines on skin cancers covered by this document.^{187,194-197} Panel members were not provided detailed, explicit cost information in determining their appropriate use ratings, although they were provided access to 8 published US studies with related information.¹⁹⁸⁻²⁰⁵ In review of this information, they were asked to implicitly consider cost as an additional factor in their evaluation of appropriate use.

For each meeting of the RP, panel members were provided a blinded summary of the group's scores with their own ratings highlighted for reference and comparison. The rating of each indication was facilitated using a 9-point scale, broken out as follows:

*Anticipated clinical benefits of MMS may include high cure rate related to total margin assessment, low rate of recurrence, small defect size, range of reconstructive possibilities, retention of functional capacity, and low morbidity and mortality.

Score 7 to 9. The use of MMS is *appropriate* for the specific indication and is generally considered acceptable.

Score 4 to 6. The use of MMS is *uncertain* for the specific indication, although its use may be appropriate and acceptable. Uncertainty implies that more research is needed to classify the indication definitively.

Score 1 to 3. The use of MMS is *inappropriate* for the specific indication and is generally not considered acceptable.

In rating each indication, the following definition of appropriate use was provided to the panel: "An appropriate treatment modality is one in which the anticipated clinical benefit* combined with clinical judgment, exceeds the possible negative consequences** for a specific indication."

**Negative clinical consequences of MMS may include the possible risks of an extended surgical procedure under local anesthesia, risk of incorrectly interpreted margins, and risks associated with office-based surgery.

Consensus is defined as at least 12 of the 17 panel members rating the procedure within the same 3-score category (appropriate, uncertain, inappropriate). The delineation of the scoring categories into 3 levels per the RAND/UCLA appropriate use methodology is arbitrary; therefore the numeric designations should be viewed as a continuum.

The final appropriate use category was determined by the median score for each indication where consensus was achieved via the 3-round rating process. After 3 rounds of scoring, the final rating for each indication that did not reach consensus was determined via panel e-mail ballot; the round-3 median score was proposed as the final value for each of those indications. Consistent with the definition of consensus for the individual rounds of rating, if at least 12 of the 17 panel members approved the proposed score, the indication was determined to have reached consensus. The final scores generated by the RP were accepted and not altered by the AHTF or other approval bodies in keeping with the RAND/UCLA appropriateness method.

RATING CONSIDERATIONS

To prevent any inconsistencies in interpretation, specific considerations and assumptions for the appropriate use of MMS were understood by the AHTF and RP in developing and rating all indications.

1. The MMS AUC address the merits of the MMS modality alone and not in comparison with other modalities for the presented clinical scenarios. For each indication, the rating should reflect whether MMS is reasonable for the patient according to the appropriate use definition, not whether MMS is preferred over another modality. That is, the AUC are not to be translated as a comparative effectiveness document. To do the latter, it would be necessary to first determine an appropriateness rating for each possible treatment modality before true comparisons could be made, a task outside the scope of the current document.
2. Panelists may consider cost, age, and cosmesis in each clinical scenario to facilitate a rating determination as follows:
 - a. Cost may be considered in the appropriate use determination, albeit not explicitly, as a secondary consideration in relationship to clinical benefits once these have been determined for the patient represented in the

clinical indication. By considering cost in this manner, the AUC facilitate the clinical care assessment process in the environment of constrained financial resources.

- b. In developing the clinical indications, the AHTF recognized that patient age and cosmesis may also impact the clinical decision to use MMS. Yet, patient age represents a continuum with indistinct categories, and the importance of cosmesis, that is, the aim to return the patient to a near normal appearance, is similarly difficult to strictly categorize based on tumor and/or patient characteristics.
3. A clinical history and physical examination has been completed such that the clinical status of the patient can be assumed to be valid as stated in the indication (eg, healthy, immunocompromised), and the patient is determined to be a good candidate for MMS.
4. Ideally, tumor characteristics are best defined with a biopsy specimen into the deep reticular dermis, if more than a superficial lesion is suspected, as recommended by the NCCN.¹⁸⁷
5. Available data demonstrate that the initial partial biopsy specimen may misrepresent histopathological findings of final tumor characteristics²⁰⁶⁻²¹²; the later findings may supersede those of the initial biopsy specimen as the indication for consideration of MMS. In addition, if for any reason, based on tumor type/subtype, size, or location, the lesion can be assigned to more than 1 indication (eg, coexistence of 2 subtypes of BCC within the same lesion), it should be classified according to the most aggressive feature.
6. Documentation of the clinical tumor border definition may be accomplished by preoperative photography with the skin stretched to delineate the visible clinical borders: (a) with or without debulking curettage (using a centimeter ruler or relation of size by another anatomic structure); or (b) with possible use of photodynamic therapy, 5-fluorouracil, or other method. Postoperative photography to document the defect may also be considered, especially for small lesions that have a significant subepithelial component (ie, tip of the iceberg phenomenon). It is understood that photographic documentation may not be possible in a small percentage of cases because of technical difficulties.

7. The tumor is not arising in prior radiated skin, a traumatic scar, an area of osteomyelitis, or an area of chronic inflammation/ulceration unless otherwise specified.
8. The category of uncertain may be used when insufficient clinical data are available for definitive categorization or there is varying agreement regarding the appropriateness of MMS for that indication. This rating should be interpreted as indicating the need for further research and not as an indicator that MMS is inappropriate. A final rating of uncertain should not equate with grounds for denial of payment.

DEFINITIONS

Mohs micrographic surgery

As defined by the American Medical Association Current Procedural Terminology (American Medical Association, Chicago, IL), MMS is a technique for the removal of complex or ill-defined skin cancer with histologic examination of 100% of the surgical margins. It is a combination of surgical excision and surgical pathology that requires a single physician to act in 2 integrated but separate and distinct capacities: surgeon and pathologist. If either of these responsibilities is delegated to another physician who reports the services separately, these codes should not be reported. The Mohs surgeon removes the tumor tissue and maps and divides the tumor specimen into pieces, and each piece is embedded into an individual tissue block for histopathologic (hematoxylin-eosin or toluidine blue) examination. Thus, a tissue block in MMS is defined as an individual tissue piece embedded in a mounting medium for sectioning.²¹³

Areas of body

- Area H: "Mask areas" of face (central face, eyelids [including inner/outer canthi], eyebrows, nose, lips [cutaneous/mucosal/vermillion], chin, ear and periauricular skin/sulci, temple), genitalia (including perineal and perianal), hands, feet, nail units, ankles, and nipples/areola.
- Area M: Cheeks, forehead, scalp, neck, jawline, pretibial surface.
- Area L: Trunk and extremities (excluding pretibial surface, hands, feet, nail units, and ankles).

Patient characteristics

- Immunocompromised: patient with HIV, organ transplant, hematologic malignancy, or pharmacologic immunosuppression.
- Genetic syndromes: basal cell nevus syndrome, xeroderma pigmentosum, or other syndromes at high risk for skin cancer.

- Healthy: no immunosuppression, prior radiation therapy, chronic infections, or genetic syndromes.
- Prior radiated skin: patient has previously received therapeutic radiation in this area of the body.
- Patient known to have high-risk tumors: patient without other known health risk factors but with a history of unexpectedly more aggressive tumors than suggested by clinical appearance.

Tumor characteristics

Positive margin on recent excision. Unexpected tumor involvement at lateral and/or deep edges after prior excision presumed to have been definitive.

Aggressive features (eg, high-risk for recurrence)

- For BCC:
 - Morpheaform/fibrosing/sclerosing
 - Infiltrating
 - Perineural
 - Metatypical/keratotic
 - Micronodular
- For SCC:
 - Sclerosing
 - Basosquamous (excluding keratotic BCC)
 - Small cell
 - Poorly or undifferentiated (characterized by a high degree of nuclear polymorphism, high mitotic rate, or low degree of keratinization)
 - Perineural/perivascular
 - Spindle cell
 - Pagetoid
 - Infiltrating
 - Keratoacanthoma (KA) type: central facial
 - Single cell
 - Clear cell
 - Lymphoepithelial
 - Sarcomatoid
 - Breslow depth 2 mm or greater
 - Clark level IV or greater

RESULTS

The final ratings for the appropriate use of MMS are listed by indication in [Tables I to V](#), and summarized by final rating category in [Table VI](#). The final score reflects the median score of the 17 RP members, and is labeled according to the 3 appropriate use categories as appropriate (median 7-9), uncertain (median 4-6), and inappropriate (median 1-3).

A total of 270 clinical scenarios were evaluated by the RP. After 3 rounds of scoring, the RP reached consensus on 205 (75.93%) scenarios with 168 (81.95%) of those scenarios deemed as appropriate,

Table I. Basal cell carcinoma

| A. Recurrent BCC of any size, or unexpected positive margin on recent excision (healthy or immunocompromised patients, or patients with genetic syndromes) | | | | |
|------------------------------------------------------------------------------------------------------------------------------------------------------------|-------------|-----------------------------|--------|--------|
| | | Appropriate use score (1-9) | | |
| Indication | Pathology | Area H | Area M | Area L |
| 1 | Aggressive | A (9) | A (9) | A (7) |
| 2 | Nodular | A (9) | A (8) | A (7) |
| 3 | Superficial | A (7) | A (7) | I (3) |
| B. Primary aggressive BCC (healthy or immunocompromised patients) | | | | |
| | | Appropriate use score (1-9) | | |
| Indication | Size, cm | Area H | Area M | Area L |
| 4 | ≤0.5 | A (8) | A (8) | U (6) |
| 5 | 0.6-1 | A (9) | A (8) | A (7) |
| 6 | 1.1-2 | A (9) | A (9) | A (8) |
| 7 | >2 | A (9) | A (9) | A (8) |
| C. Primary nodular BCC (healthy patients) | | | | |
| | | Appropriate use score (1-9) | | |
| Indication | Size, cm | Area H | Area M | Area L |
| 8 | ≤0.5 | A (7) | A (7) | I (3) |
| 9 | 0.6-1 | A (8) | A (8) | I (3) |
| 10 | 1.1-2 | A (9) | A (8) | U (6) |
| 11 | >2 | A (9) | A (9) | A (7) |
| D. Primary nodular BCC (immunocompromised patients) | | | | |
| | | Appropriate use score (1-9) | | |
| Indication | Size, cm | Area H | Area M | Area L |
| 12 | ≤0.5 | A (8) | A (7) | I (3) |
| 13 | 0.6-1 | A (9) | A (8) | U (5) |
| 14 | 1.1-2 | A (9) | A (9) | A (7) |
| 15 | >2 | A (9) | A (9) | A (7) |
| E. Primary superficial BCC (healthy patients) | | | | |
| | | Appropriate use score (1-9) | | |
| Indication | Size, cm | Area H | Area M | Area L |
| 16 | ≤0.5 | A (7) | U (4) | I (1) |
| 17 | 0.6-1 | A (7) | A (7) | I (3) |
| 18 | 1.1-2 | A (7) | A (7) | I (3) |
| 19 | >2 | A (8) | A (8) | I (3) |
| F. Primary superficial BCC (immunocompromised patients) | | | | |
| | | Appropriate use score (1-9) | | |
| Indication | Size, cm | Area H | Area M | Area L |
| 20 | ≤0.5 | A (7) | A (7) | I (2) |
| 21 | 0.6-1 | A (8) | A (7) | I (3) |
| 22 | 1.1-2 | A (8) | A (7) | U (5) |
| 23 | >2 | A (8) | A (8) | U (5) |

Appropriate use scores and final ratings for 69 BCC indications. Appropriate indications (A; scores 7-9) are colored green; Uncertain indications (U; scores 4-6) are colored yellow; Inappropriate indications (I; scores 1-3) are colored red.

Area H: 'Mask areas' of face (central face, eyelids [including inner/outer canthi], eyebrows, nose, lips [cutaneous/mucosal/vermillion], chin, ear and periauricular skin /sulci, temple), genitalia (including perineal and perianal), hands, feet, nail units, ankles, and nipples/areola.

Area M: Cheeks, forehead, scalp, neck, jawline, pretibial surface.

Area L: Trunk and extremities (excluding pretibial surface, hands, feet, nail units and ankles).

BCC, Basal cell carcinoma.

Table II. Squamous cell carcinoma

| A. Recurrent SCC of any size or unexpected positive margin on recent excision (healthy or immunocompromised patients, or patients with genetic syndromes) | | | | |
|--------------------------------------------------------------------------------------------------------------------------------------------------------------|----------------------------------------------------------------------------------------------------------------|-----------------------------|--------|--------|
| | | Appropriate use score (1-9) | | |
| Indication | Pathology | Area H | Area M | Area L |
| 24 | Aggressive | A (9) | A (9) | A (8) |
| 25 | Verrucous | A (9) | | |
| 26 | KA-type SCC (not central facial) | A (8) | A (8) | A (7) |
| 27 | In situ/Bowen | A (7) | A (7) | U (6) |
| 28 | AK with focal SCC in situ; Bowenoid AK; SCC in situ, AK type | I (2) | I (2) | I (2) |
| 29 | Without aggressive histologic features, <2-mm depth without other defining features, Clark level ≤III | A (8) | A (8) | A (7) |
| B. Primary aggressive SCC (healthy patients) | | | | |
| | | Appropriate use score (1-9) | | |
| Indication | Size, cm | Area H | Area M | Area L |
| 30 | ≤0.5 | A (8) | A (8) | A (7) |
| 31 | 0.6-1 | A (9) | A (8) | A (7) |
| 32 | 1.1-2 | A (9) | A (9) | A (7) |
| 33 | >2 | A (9) | A (9) | A (8) |
| C. Primary aggressive SCC (immunocompromised patients) | | | | |
| | | Appropriate use score (1-9) | | |
| Indication | Size, cm | Area H | Area M | Area L |
| 34 | ≤0.5 | A (9) | A (8) | A (7) |
| 35 | 0.6-1 | A (9) | A (8) | A (7) |
| 36 | 1.1-2 | A (9) | A (9) | A (8) |
| 37 | >2 | A (9) | A (9) | A (9) |
| D. Primary SCC; without aggressive histologic features, <2-mm depth without other defining features, Clark level ≤III (healthy patients) | | | | |
| | | Appropriate use score (1-9) | | |
| Indication | Size, cm | Area H | Area M | Area L |
| 38 | ≤0.5 | A (8) | A (7) | I (3) |
| 39 | 0.6-1 | A (8) | A (7) | I (3) |
| 40 | 1.1-2 | A (8) | A (8) | U (6) |
| 41 | >2 | A (9) | A (9) | A (7) |
| E. Primary SCC; without aggressive histologic features, <2-mm depth without other defining features, Clark level ≤III (immunocompromised patients) | | | | |
| | | Appropriate use score (1-9) | | |
| Indication | Size, cm | Area H | Area M | Area L |
| 42 | ≤0.5 | A (8) | A (8) | U (5) |
| 43 | 0.6-1 | A (9) | A (8) | U (6) |
| 44 | 1.1-2 | A (9) | A (9) | A (7) |
| 45 | >2 | A (9) | A (9) | A (8) |
| F. Primary verrucous SCC (healthy or immunocompromised patients) | | | | |
| | | Appropriate use score (1-9) | | |
| Indication | Size, cm | Area H | Area M | Area L |
| 46 | ≤0.5 | A (8) | | |
| 47 | 0.6-1 | A (8) | | |
| 48 | 1.1-2 | A (9) | | |
| 49 | >2 | A (9) | | |

Continued

Table II. Cont'd

| G. Primary SCC KA-type; not central facial (healthy patients) | | | | |
|------------------------------------------------------------------------------------------------------|----------|-----------------------------|--------|--------|
| | | Appropriate use score (1-9) | | |
| Indication | Size, cm | Area H | Area M | Area L |
| 50 | ≤0.5 | A (7) | A (7) | I (2) |
| 51 | 0.6-1 | A (8) | A (7) | I (3) |
| 52 | 1.1-2 | A (9) | A (8) | A (7) |
| 53 | >2 | A (9) | A (9) | A (7) |
| H. Primary SCC KA-type; not central facial (immunocompromised patients) | | | | |
| | | Appropriate use score (1-9) | | |
| Indication | Size, cm | Area H | Area M | Area L |
| 54 | ≤0.5 | A (8) | A (7) | U (6) |
| 55 | 0.6-1 | A (8) | A (8) | A (7) |
| 56 | 1.1-2 | A (9) | A (8) | A (7) |
| 57 | >2 | A (9) | A (9) | A (8) |
| I. Primary in situ SCC/Bowen disease (healthy patients) | | | | |
| | | Appropriate use score (1-9) | | |
| Indication | Size, cm | Area H | Area M | Area L |
| 58 | ≤0.5 | A (7) | A (7) | I (2) |
| 59 | 0.6-1 | A (7) | A (7) | I (2) |
| 60 | 1.1-2 | A (8) | A (8) | U (6) |
| 61 | >2 | A (9) | A (8) | A (7) |
| J. Primary in situ SCC/Bowen disease (immunocompromised patients) | | | | |
| | | Appropriate use score (1-9) | | |
| Indication | Size, cm | Area H | Area M | Area L |
| 62 | ≤0.5 | A (8) | A (7) | I (3) |
| 63 | 0.6-1 | A (8) | A (7) | U (4) |
| 64 | 1.1-2 | A (8) | A (8) | A (7) |
| 65 | >2 | A (9) | A (8) | A (7) |
| K. Primary AK with focal SCC in situ; Bowenoid AK; SCC in situ, AK type (healthy patients) | | | | |
| | | Appropriate use score (1-9) | | |
| Indication | Size, cm | Area H | Area M | Area L |
| 66 | ≤0.5 | I (3) | I (2) | I (1) |
| 67 | 0.6-1 | I (3) | I (2) | I (1) |
| 68 | 1.1-2 | I (3) | I (3) | I (1) |
| 69 | >2 | I (3) | I (3) | I (2) |
| L. Primary AK with focal SCC in situ; Bowenoid AK; SCC in situ, AK type (immunocompromised patients) | | | | |
| | | Appropriate use score (1-9) | | |
| Indication | Size, cm | Area H | Area M | Area L |
| 70 | ≤0.5 | I (2) | I (2) | I (1) |
| 71 | 0.6-1 | I (2) | I (2) | I (2) |
| 72 | 1.1-2 | I (2) | I (2) | I (2) |
| 73 | >2 | I (2) | I (2) | I (2) |

Appropriate use scores and final ratings for 140 SCC indications. Appropriate indications (A; scores 7-9) are colored green; Uncertain indications (U; scores 4-6) are colored yellow; Inappropriate indications (I; scores 1-3) are colored red.

Black boxes indicate areas not assessed or scored by the ratings panel.

Area H: 'Mask areas' of face (central face, eyelids [including inner/outer canthi], eyebrows, nose, lips [cutaneous/mucosal/vermillion], chin, ear and periauricular skin /sulci, temple), genitalia (including perineal and perianal), hands, feet, nail units, ankles, and nipples/areola.

Area M: Cheeks, forehead, scalp, neck, jawline, pretibial surface.

Area L: Trunk and extremities (excluding pre-tibial surface, hands, feet, nail units and ankles).

AK, Actinic keratosis; KA, keratoacanthoma; SCC, squamous cell carcinoma.

Table III. Basal or squamous cell carcinoma

| Primary BCC or SCC regardless of subtype, size, or depth arising in: | | | |
|----------------------------------------------------------------------------------------------------------------------------------------------------------------------------------------------------------------------------------|--------------|--------------|--------------|
| <ul style="list-style-type: none"> • Prior radiated skin • Traumatic scar • Area of osteomyelitis • Area of chronic inflammation/ulceration • Patients with genetic syndromes | | | |
| Appropriate use score (1-9) | | | |
| Indication | Area H | Area M | Area L |
| 74 | A (9) | A (9) | A (7) |

Appropriate use scores and final ratings for 3 combined BCC or SCC indications. Appropriate indications (A; scores 7-9) are colored green. Area H: 'Mask areas' of face (central face, eyelids [including inner/outer canthi], eyebrows, nose, lips [cutaneous/mucosal/vermillion], chin, ear and periauricular skin /sulci, temple), genitalia (including perineal and perianal), hands, feet, nail units, ankles, and nipples/areola. Area M: Cheeks, forehead, scalp, neck, jawline, pretibial surface. Area L: Trunk and extremities (excluding pretibial surface, hands, feet, nail units and ankles). BCC, Basal cell carcinoma; SCC, squamous cell carcinoma.

Table IV. Lentigo maligna and melanoma in situ

| A. Primary lentigo maligna (healthy or immunocompromised patients) | | | |
|-----------------------------------------------------------------------------------------------------------|--------------|--------------|--------------|
| Appropriate use score (1-9) | | | |
| Indication | Area H | Area M | Area L |
| 75 | A (8) | A (7) | U (4) |
| B. Locally recurrent lentigo maligna (healthy or immunocompromised patients) | | | |
| Appropriate use score (1-9) | | | |
| Indication | Area H | Area M | Area L |
| 76 | A (8) | A (8) | A (7) |
| C. Primary melanoma in situ; non-lentigo maligna (healthy or immunocompromised patients) | | | |
| Appropriate use score (1-9) | | | |
| Indication | Area H | Area M | Area L |
| 77 | A (7) | A (7) | U (5) |
| D. Locally recurrent melanoma in situ; non-lentigo maligna (healthy or immunocompromised patients) | | | |
| Appropriate use score (1-9) | | | |
| Indication | Area H | Area M | Area L |
| 78 | A (8) | A (7) | A (7) |

Appropriate use scores and final ratings for 12 lentigo maligna and melanoma in situ indications.

Appropriate indications (A; scores 7-9) are colored green; Uncertain indications (U; scores 4-6) are colored yellow.

Area H: 'Mask areas' of face (central face, eyelids [including inner/outer canthi], eyebrows, nose, lips [cutaneous/mucosal/vermillion], chin, ear and periauricular skin /sulci, temple), genitalia (including perineal and perianal), hands, feet, nail units, ankles, and nipples/areola.

Area M: Cheeks, forehead, scalp, neck, jawline, pretibial surface.

Area L: Trunk and extremities (excluding pretibial surface, hands, feet, nail units and ankles).

0 (0%) as uncertain, and 37 (18.05%) as inappropriate. A total of 65 (24.07%) scenarios did not reach consensus, and reflected a round-3 median score of 32 appropriate, 24 uncertain, and 9 inappropriate. For these 65 scenarios, an e-mail ballot was circulated to the RP in an effort to attain a greater degree of consensus, based on the approach previously used

by the American College of Radiology.¹⁹³ All 65 of these indications reached consensus as a result.

After RP evaluations had concluded (3 rating sessions and the e-mail ballot), all 270 (100%) scenarios reached consensus. Of those, 200 (74.07%) were deemed appropriate, 24 (8.89%) uncertain, and 46 (17.04%) inappropriate.

Table V. Less common skin cancers

| Primary or recurrent (healthy or immunocompromised patients) | | Appropriate use score (1-9) | | |
|--------------------------------------------------------------|---------------------------------------------------------|-----------------------------|--------|--------|
| Indication | Cancer type | Area H | Area M | Area L |
| 79 | Adenocystic carcinoma | A (9) | A (8) | A (7) |
| 80 | Adnexal carcinoma | A (9) | A (8) | A (7) |
| 81 | Apocrine/eccrine carcinoma | A (8) | A (8) | A (8) |
| 82 | Angiosarcoma | U (5) | U (5) | U (5) |
| 83 | AFX | A (9) | A (8) | A (7) |
| 84 | Bowenoid papulosis | I (3) | | |
| 85 | DFSP | A (9) | A (9) | A (9) |
| 86 | Desmoplastic trichoepithelioma | U (6) | U (5) | I (3) |
| 87 | EMPD | A (8) | A (8) | A (7) |
| 88 | Leiomyosarcoma | A (8) | A (8) | A (7) |
| 89 | MFH/undifferentiated pleomorphic sarcoma | A (8) | A (8) | A (7) |
| 90 | MCC | A (8) | A (7) | U (5) |
| 91 | MAC (sclerosing sweat duct carcinoma) | A (9) | A (9) | A (8) |
| 92 | Mucinous carcinoma | A (8) | A (8) | A (7) |
| 93 | Sebaceous carcinoma | A (9) | A (8) | A (7) |
| 94 | Rare biopsy-proven malignancies not otherwise specified | U (5) | U (5) | U (5) |

Appropriate use scores and final ratings for 46 indications for less common cancers. Appropriate indications (A; scores 7-9) are colored green; Uncertain indications (U; scores 4-6) are colored yellow; Inappropriate indications (I; scores 1-3) are colored red.

Black boxes indicate areas not assessed or scored by the ratings panel.

Area H: 'Mask areas' of face (central face, eyelids [including inner/outer canthi], eyebrows, nose, lips [cutaneous/mucosal/vermillion], chin, ear and periauricular skin /sulci, temple), genitalia (including perineal and perianal), hands, feet, nail units, ankles, and nipples/areola.

Area M: Cheeks, forehead, scalp, neck, jawline, pretibial surface.

Area L: Trunk and extremities (excluding pretibial surface, hands, feet, nail units and ankles).

AFX, Atypical fibroxanthoma; DFSP, dermatofibrosarcoma protuberans; EMPD, extramammary Paget disease; MAC, microcystic adnexal carcinoma; MCC, Merkel cell carcinoma; MFH, malignant fibrous histiocytoma.

Within the 69 scenarios of BCC (Tables I and III), 53 (76.81%) were deemed appropriate, 6 (8.70%) uncertain, and 10 (14.49%) inappropriate, with consensus reached for all indications. All forms of BCC (indications 1-23) including recurrent, primary aggressive, primary nodular, and primary superficial were rated appropriate on areas H and M regardless of size or patient type, with the exception of primary superficial BCC 0.5 cm or smaller in area M for healthy patients, which received a rating of uncertain (indication 16). When located on the trunk and extremities (area L), recurrent superficial BCC, primary nodular BCC 1 cm or smaller in healthy individuals, primary nodular BCC 0.5 cm or smaller in immunocompromised patients, and primary superficial BCC of any size in healthy patients, or 1 cm or smaller in immunocompromised patients (indications 3, 8, 9, 12, and 16-21) were all deemed inappropriate for the use of MMS. Also, when located on the trunk and extremities (area L) primary aggressive BCC 0.5 cm or smaller, primary nodular BCC 1.1 to 2 cm in healthy patients and 0.6 to 1 cm in immunocompromised patients, along with primary superficial BCC larger than 1 cm in immunocompromised patients (indications 4, 10, 13, 22, and 23) were all deemed as uncertain.

Within the 143 scenarios for SCC (Tables II and III), 102 (71.33%) were appropriate, 7 (4.90%) uncertain, and 34 (23.78%) inappropriate, with consensus reached for all indications. The use of MMS for recurrent SCC with or without aggressive histologic features and KA-type SCC was determined to be appropriate in all areas, and appropriate in area H for recurrent verrucous SCC (indications 24-26 and 29). Primary aggressive SCC of any size (indications 30-37) was also deemed appropriate in all locations for both healthy and immunocompromised patients. Primary SCC without aggressive histologic features was appropriate in areas H and M for any size tumor (indications 38-40), and appropriate in all locations when larger than 2 cm in healthy patients (indication 41). For immunocompromised patients, primary SCC without aggressive histologic features was appropriate in areas H and M when 1 cm or smaller (indications 42 and 43), and appropriate in all locations when larger than 1 cm (indications 44 and 45). Primary verrucous SCC of any size (indications 46-49) was appropriate in area H regardless of patient type. Primary SCC KA type (not central facial) was appropriate in areas H and M when 1 cm or smaller (indications 50 and 51), and appropriate in all locations when larger than

Table VI. Ratings category summary for basal cell carcinoma, squamous cell carcinoma, lentigo maligna, and melanoma in situ

| AREA H | Appropriate | Uncertain | Inappropriate |
|-------------------|-----------------------------------------------------------------------------------------------------------------------------------------------------------------------------------------------------------------------------------------------------------------------------------------------------------------|-------------------------------------------------------------------------------------------------------------------------------------------------------------------------------------------------------------------------------------------------|-------------------------------------------------------------------------------------------------------------------------------------------------------------------------------------------------|
| BCC | Primary or recurrent: Aggressive Nodular Superficial | | |
| SCC | Primary or recurrent: Aggressive Nonaggressive* Verrucous KA-type SCC [†] In situ SCC/Bowen | | Primary or recurrent: AK with focal SCC in situ |
| LM and MIS | Primary or recurrent: LM MIS | | |
| AREA M | Appropriate | Uncertain | Inappropriate |
| BCC | Recurrent or primary: Aggressive Nodular Superficial (IC) Primary: Superficial ≥ 0.6 cm | Primary: Superficial ≤ 0.5 cm | |
| SCC | Primary or recurrent: Aggressive Nonaggressive* KA-type SCC [†] In situ SCC/Bowen | | Primary or recurrent: AK with focal SCC in situ |
| LM and MIS | Primary or recurrent: LM MIS | | |
| AREA L | Appropriate | Uncertain | Inappropriate |
| BCC | Recurrent: Aggressive Nodular Primary: Aggressive ≥ 0.6 cm Nodular > 2 cm Nodular (IC) ≥ 1.1 cm | Primary: Aggressive ≤ 0.5 cm Nodular 1.1-2 cm Nodular (IC) 0.6-1 cm Superficial (IC) ≥ 1.1 cm | Recurrent Superficial Primary: Nodular ≤ 1 cm Nodular (IC) ≤ 0.5 cm Superficial Superficial (IC) ≤ 1 cm |
| SCC | Primary or recurrent: Aggressive Recurrent: KA-type SCC [†] Nonaggressive* Primary > 2 cm Nonaggressive* In situ SCC/Bowen Primary ≥ 1.1 cm Nonaggressive (IC)* KA-type SCC [†] In situ SCC/Bowen (IC) KA-type SCC (IC) ≥ 0.6 cm [†] | Recurrent SCC in situ/Bowen Primary 1.1-2 cm Nonaggressive* SCC in situ/Bowen Primary ≤ 1 cm Nonaggressive (IC)* Primary 0.6-1 cm SCC in situ/Bowen (IC) Primary ≤ 0.5 cm KA-type SCC (IC) [†] | Primary or recurrent: AK with focal SCC in situ Primary ≤ 1 cm Nonaggressive* KA-type SCC [†] SCC in situ/Bowen Primary ≤ 0.5 cm SCC in situ/Bowen (IC) |
| LM and MIS | Recurrent: LM MIS | Primary: LM MIS | |

Listed indications are for both healthy and IC patients, and tumors of any size unless otherwise specified.

Area H: 'Mask areas' of face (central face, eyelids [including inner/outer canthi], eyebrows, nose, lips [cutaneous/mucosal/vermillion], chin, ear and periauricular skin /sulci, temple), genitalia (including perineal and perianal), hands, feet, nail units, ankles, and nipples/areola.

Area M: Cheeks, forehead, scalp, neck, jawline, pretibial surface.

Area L: Trunk and extremities (excluding pretibial surface, hands, feet, nail units and ankles).

AK, Actinic keratosis; BCC, basal cell carcinoma; KA, keratoacanthoma; IC, immunocompromised; LM, lentigo maligna; MIS, melanoma in situ; SCC, squamous cell carcinoma.

*SCC without aggressive features, <2 -mm depth without other defining features, Clark level \leq III.

[†]Not central facial.

1 cm in healthy patients (indications 52 and 53). For immunocompromised patients, primary SCC KA type (not central facial) was appropriate in areas H and M when 0.5 cm or smaller (indication 54), and appropriate in all locations when 0.6 cm or larger (indications 55-57). Primary in situ SCC/Bowen disease in healthy patients was appropriate in areas H and M when 2 cm or smaller (indications 58-60), and appropriate in all locations when larger than 2 cm (indication 61). For immunocompromised patients, primary in situ SCC/Bowen disease was appropriate in areas H and M for tumors of any size (indications 62-65), and appropriate in all locations when larger than 1 cm (indications 64 and 65). Primary BCC or SCC regardless of subtype, size, or depth were all deemed appropriate in all areas when arising in prior radiated skin, a traumatic scar, areas of osteomyelitis, areas of chronic inflammation/ulceration, or in patients with genetic syndromes (indication 74).

When located on the trunk and extremities (area L), primary SCC without aggressive histologic features, primary SCC KA type (not central facial), and primary in situ SCC/Bowen disease 1 cm or smaller in healthy patients were deemed inappropriate (indications 38, 39, 50, 51, 58, and 59). Similarly, primary in situ SCC/Bowen disease 0.5 cm or smaller in immunocompromised patients (indication 62) was also inappropriate in area L. Finally, both recurrent and primary actinic keratosis with focal SCC in situ (Bowenoid actinic keratosis; SCC in situ, actinic keratosis type) of any size was inappropriate in all areas in both healthy and immunocompromised patients (indications 28 and 66-73).

A number of SCC scenarios remain uncertain in area L including primary SCC 1.1 to 2 cm without aggressive histologic features in healthy patients (indication 40) and 1 cm or smaller in immunocompromised patients (indications 42 and 43), primary SCC KA type (not central facial) 0.5 cm or smaller in immunocompromised patients (indication 54), recurrent in situ/Bowen disease (indication 27), and primary in situ SCC/Bowen disease 1.1 to 2 cm in healthy patients (indication 60) and 0.6 to 1 cm in immunocompromised patients (indication 63).

Of the 12 clinical scenarios for LM, melanoma in situ (Table IV), 10 (83.33%) were deemed appropriate, 2 (16.67%) uncertain, and 0 (0%) inappropriate with consensus reached for all scenarios. MMS was deemed appropriate for primary LM and primary melanoma in situ (non-LM) in areas H and M for healthy and immunocompromised patients (indications 75 and 77). Locally recurrent LM and melanoma in situ (non-LM) was rated appropriate for MMS in all

locations for both healthy and immunocompromised patients (indications 76 and 78). The use of MMS for primary LM and for primary melanoma in situ in healthy or immunocompromised patients was determined to be uncertain when located on area L (indications 75 and 77).

MMS was also deemed appropriate for adenocystic carcinoma, adnexal carcinoma, apocrine/eccrine carcinoma, atypical fibroxanthoma, dermatofibrosarcoma protuberans, extramammary Paget disease, leiomyosarcoma, malignant fibrous histiocytoma (undifferentiated pleomorphic sarcoma), microcystic adnexal carcinoma (sclerosing sweat duct carcinoma), mucinous carcinoma, and sebaceous carcinoma in all locations regardless of patient type (Table V) (indications 79-81, 83, 85, 87-89, and 91-93). MMS for MCC was determined to be appropriate in areas H and M (indication 90). The AUC for MCC were determined by considering MMS as monotherapy, and the possibility of adjuvant radiation therapy was not factored into the final AUC decision.

Angiosarcoma in all locations, desmoplastic trichoepithelioma in areas H and M, and MCC in area L were deemed uncertain (indications 82, 86, and 90). Bowenoid papulosis in area H and desmoplastic trichoepithelioma in area L received a rating of inappropriate (indications 84 and 86). Lastly, rare biopsy-proven malignancies not otherwise specified were deemed uncertain for the use of MMS in all areas (indication 94).

DISCUSSION

AUC are often used to define when it is reasonable to use a particular procedure in the context of available medical information, expert clinical opinion, patient characteristics, and the health care environment. The intent of these AUC is to provide guidance for the rational use of MMS in the practice setting. In doing so, this document can provide physicians with practical information to facilitate both clinical decision making and provider-patient dialogue about treatment options for cutaneous malignancies that may include MMS. The goal of these AUC is not to directly address cost-related concerns, but rather to ensure that MMS is used for clinically appropriate indications. Ideally, these AUC will support optimum and justified health care expenditures and improved health care delivery, while providing patients with high-quality care and clinical outcomes.

This document is the first AUC for MMS and also represents the first AUC for any test or treatment option within dermatology. Importantly, this AUC document is not comparative for different treatment

modalities used to treat cutaneous malignancy, but is a document that pertains solely to the use of MMS and the appropriateness of MMS in certain clinical scenarios. AUC pertaining to other treatment modalities of cutaneous malignancy may be forthcoming. It should also be understood that the initial biopsy specimen of a cutaneous malignancy that prompts categorization of appropriate use of MMS may misrepresent the true histopathological findings of final tumor characteristics, particularly if the initial biopsy specimen is superficial or partial.²⁰⁶⁻²¹² Thus it is important when using the AUC documented herein that an appropriate and accurate biopsy of the represented cutaneous malignancy has been performed, as these clinical scenarios pertain to well-defined pathologic diagnoses.

The rating of these targeted clinical scenarios as appropriate, uncertain, or inappropriate is a reflection of the body of knowledge of the members of the RP at the time of the rating process. It is possible that as medical knowledge increases and new evidence-based guidelines are published and become available, certain clinical scenarios in this document may be determined to have a different appropriateness rating than what has been outlined herein. Whenever possible, published clinical information was used to determine appropriateness; however, in many scenarios where evidence-based information was lacking, clinical expertise played a significant role in determining the appropriateness of scenarios. Thus, this document is intended as a living revisable document that will need to be reviewed and modified as new data become available pertaining to the appropriate use of MMS. Given the patient-centered approach of the AUC process, it is hoped that this document will be used to direct further research to facilitate more definitive classification in future revisions for all clinical scenarios currently classified as uncertain. In addition, further refinement or separation of some clinical scenarios to more clearly delineate specific patient or tumor characteristics may impact these ratings and facilitate more precise patient selection for MMS. It may be beneficial in the future to further segregate patient groups such as healthy, immunocompromised, or those with genetic syndromes into distinct indications for all tumor types and locations. For example, the AHTF recognizes the rating of appropriate for indication 74 in area L, yet the anomalous rating of inappropriate for indication 3 in area L.

Although the appropriate use ratings reflect critical medical literature and expert consensus, physicians and other stakeholders should understand the role of clinical judgment in determining treatment approaches for an individual patient. The clinical

scenarios identified in this document are crafted for the average patient and not the exception. Thus, the ultimate decision regarding the appropriateness of MMS should be determined by the expertise and clinical experience of the physician when considering any individual patient's specific and unique characteristics. However, although individual exceptions to the ratings are both anticipated and justified, the performance of MMS not supported by medical literature or expert consensus should be minimized.

In addition, uncertain indications often require individual physician judgment and understanding of the patient and other clinical factors to better determine the appropriateness of MMS for a particular scenario. As such, the ranking of uncertain should not be viewed as limiting the use of MMS for patients. Importantly for these AUC, RP members were instructed in determining an appropriateness ranking that a designation of uncertain was designed to be reimbursable when determined appropriate via the clinician's discretion. A final rating in this "uncertain" category does, however, facilitate a better understanding of scenarios of MMS that would benefit most from further research.

In conclusion, this document represents the current understanding and clinical judgment as to the appropriateness of MMS using the framework of the AUC methodology. It will be necessary to periodically assess and update these indications and ratings as further research, expanding clinical experience, and the evolution of the practice of MMS is brought forth, so as to provide the greatest benefit to clinical decision making, optimization of health care expenditures, and impact on quality patient care.

APPENDIX

The supporting evidence tables for these AUC may be found at the AAD World Wide Web site: <http://www.aad.org/education-and-quality-care/appropriate-use-criteria/mohs-surgery-auc>.

The AHTF thanks the following individuals for their thoughtful review of draft clinical indications, evidence tables, and AUC terminology: Rex Amonette, MD; Maryam Asgari, MD; Richard Bennett, MD; Jeremy Bordeaux, MD; Darryl Bronson, MD; Hank Clever, MD; Clara Curiel, MD; Scott Dinehart, MD; Leonard Dzubow, MD; Roy Geronemus, MD; Hayes Gladstone, MD; David Goldberg, MD; Leonard Goldberg, MD; Hugh Greenway, MD; Warren Heymann, MD; Hillary Johnson-Jahangir, MD; John Maize, MD; Mary Maloney, MD; William Mangold, MD; Ashfaq Marghoob, MD; Vic Marks, MD; John Martinez, MD; Alexander Miller, MD; Brent Moody, MD; Vince

Muscarella, MD; Marcy Neuburg, MD; Isaac Neuhaus, MD; Elise Olsen, MD; Steve Padilla, MD; Elizabeth Page, MD; Mark Pittlekow, MD; Jeanette Pitts, MD; Abrar Qureshi, MD; Robert Rosenberg, MD; Erik Stratman, MD; George Stricklin, MD; Neil Swanson, MD; Robert Swerlick, MD; Michael Tharp, MD; Kenneth Tomecki, MD; Jeffrey Travers, MD; Hensin Tsao, MD; Carl Washington, MD; Susan Weinkle, MD; Christopher Zachary, MD; and Michael Zanolli, MD. The AHTF also thanks the following individuals for their technical support in the development of the MMS AUC evidence tables: Scott Freeman, MD; Kyle Horner, MD; Richelle Knudson, MD; Justin Ko, MD; Justin Leitenberger, MD; Mary Alice Mina, MD; Kurtis Reed, MD; Nazanin Saedi, MD; Christopher Harrod, MS; Allen McMillen, BA; and Kathleen Muldowney, MLS.

REFERENCES

- Rogers HW, Weinstock MA, Harris AR, Hinckley MR, Feldman SR, Fleischer AB, et al. Incidence estimate of nonmelanoma skin cancer in the United States, 2006. *Arch Dermatol* 2010; 146:283-7.
- American Cancer Society. Cancer facts and figures 2012. Available from: URL:<http://www.cancer.org/acs/groups/content/@epidemiologysurveillance/documents/document/acspc-031941.pdf>. Accessed March 1, 2012.
- Swetter SM, Boldrick JC, Jung SY, Egbert BM, Harvell JD. Increasing incidence of lentigo maligna melanoma subtypes: northern California and national trends 1990-2000. *J Invest Dermatol* 2005;125:685-91.
- Asgari MM, Olson JM, Alam M. Needs assessment for Mohs micrographic surgery. *Dermatol Clin* 2012;30:167-75, x.
- Mohs FE. *Chemosurgery: microscopically controlled surgery for skin cancer*. Springfield, IL: Charles C. Thomas; 1978.
- Anderson RL. Results in eyelid malignancies treated with the Mohs fresh-tissue technique. *Trans New Orleans Acad Ophthalmol* 1982;30:380-91.
- Asgari MM, Bertenthal D, Sen S, Sahay A, Chren MM. Patient satisfaction after treatment of nonmelanoma skin cancer. *Dermatol Surg* 2009;35:1041-9.
- Bailin PL, Levine HL, Wood BG, Tucker HM. Cutaneous carcinoma of the auricular and periauricular region. *Arch Otolaryngol* 1980;106:692-6.
- Barrett TL, Greenway HT Jr, Massullo V, Carlson C. Treatment of basal cell carcinoma and squamous cell carcinoma with perineural invasion. *Adv Dermatol* 1993;8:277-305.
- Batra RS, Kelley LC. Predictors of extensive subclinical spread in nonmelanoma skin cancer treated with Mohs micrographic surgery. *Arch Dermatol* 2002;138:1043-51.
- Bentkover SH, Grande DM, Soto H, Kozlicak BA, Guillaume D, Girouard S. Excision of head and neck basal cell carcinoma with a rapid, cross-sectional, frozen-section technique. *Arch Facial Plast Surg* 2002;4:114-9.
- Bielewicz HC, Kirsner RS, Reyes BA, Garland LD. The use of Mohs micrographic surgery for determination of residual tumor in incompletely excised basal cell carcinoma. *J Am Acad Dermatol* 1992;26:754-6.
- Bowman PH, Ratz JL, Knoepp TG, Barnes CJ, Finley EM. Basosquamous carcinoma. *Dermatol Surg* 2003;29:830-3.
- Brown MD, Zachary CB, Grekin RC, Swanson NA. Genital tumors: their management by micrographic surgery. *J Am Acad Dermatol* 1988;18:115-22.
- Bumsted RM, Ceilley RI. Auricular malignant neoplasms: identification of high-risk lesions and selection of method of reconstruction. *Arch Otolaryngol* 1982;108: 225-31.
- Bumsted RM, Ceilley RI, Panje WR, Crumley RL. Auricular malignant neoplasms: when is chemotherapy (Mohs' technique) necessary? *Arch Otolaryngol* 1981;107:721-4.
- Callahan MA, Monheit GD, Callahan A. Cancer excision from eyelids and ocular adnexa: the Mohs' fresh tissue technique and reconstruction; a five-year study of 109 patients. *Ala J Med Sci* 1983;20:289-94.
- Carter KD, Nerad JA, Whitaker DC. Clinical factors influencing periocular surgical defects after Mohs micrographic surgery. *Ophthalm Plast Reconstr Surg* 1999;15:83-91.
- Ceilley RI, Anderson RL. Microscopically controlled excision of malignant neoplasms on and around eyelids followed by immediate surgical reconstruction. *J Dermatol Surg Oncol* 1978;4:55-62.
- Chren MM, Sahay AP, Bertenthal DS, Sen S, Landefeld CS. Quality-of-life outcomes of treatments for cutaneous basal cell carcinoma and squamous cell carcinoma. *J Invest Dermatol* 2007;127:1351-7.
- Clark DP, Hanke CW. Neoplasms of the conchal bowl: treatment with Mohs micrographic surgery. *J Dermatol Surg Oncol* 1988;14:1223-8.
- Dinehart SM, Dodge R, Stanley WE, Franks HH, Pollack SV. Basal cell carcinoma treated with Mohs surgery: a comparison of 54 younger patients with 1050 older patients. *J Dermatol Surg Oncol* 1992;18:560-6.
- Duffy KL, McKenna JK, Hadley ML, Tristani-Firouzi P. Non-melanoma skin cancers of the ear: correlation between subanatomic location and post-Mohs micrographic surgery defect size. *Dermatol Surg* 2009;35:30-3.
- Geist DE, Garcia-Moliner M, Fitzek MM, Cho H, Rogers GS. Perineural invasion of cutaneous squamous cell carcinoma and basal cell carcinoma: raising awareness and optimizing management. *Dermatol Surg* 2008;34:1642-51.
- Gibson GE, Ahmed I. Perianal and genital basal cell carcinoma: a clinicopathologic review of 51 cases. *J Am Acad Dermatol* 2001;45:68-71.
- Goldberg LH, Leis P, Pham HN. Basal cell carcinoma on the neck. *Dermatol Surg* 1996;22:349-53.
- Hanke CW, Weisberger EC. Invasion of parotid gland by basal cell carcinoma: implications for therapy. *J Dermatol Surg Oncol* 1986;12:849-52.
- Hendrix JD Jr, Parlette HL. Duplicitous growth of infiltrative basal cell carcinoma: analysis of clinically undetected tumor extent in a paired case-control study. *Dermatol Surg* 1996;22: 535-9.
- Hruza GJ. Mohs micrographic surgery local recurrences. *J Dermatol Surg Oncol* 1994;20:573-7.
- Huang CC, Boyce S, Northington M, Desmond R, Soong SJ. Randomized, controlled surgical trial of preoperative tumor curettage of basal cell carcinoma in Mohs micrographic surgery. *J Am Acad Dermatol* 2004;51:585-91.
- Kimyai-Asadi A, Alam M, Goldberg LH, Peterson SR, Silapunt S, Jih MH. Efficacy of narrow-margin excision of well-demarcated primary facial basal cell carcinomas. *J Am Acad Dermatol* 2005;53:464-8.
- Lang PG Jr, Maize JC. Histologic evolution of recurrent basal cell carcinoma and treatment implications. *J Am Acad Dermatol* 1986;14:186-96.

33. Leffell DJ, Headington JT, Wong DS, Swanson NA. Aggressive-growth basal cell carcinoma in young adults. *Arch Dermatol* 1991;127:1663-7.
34. Leshin B, Yeatts P, Anscher M, Montano G, Dutton JJ. Management of periocular basal cell carcinoma: Mohs' micrographic surgery versus radiotherapy. *Surv Ophthalmol* 1993;38:193-212.
35. Lim KK, Randle HW, Roenigk RK, Brodland DG, Bernstein SC, Marcil I. Linear basal cell carcinoma: report of seventeen cases and review of the presentation and treatment. *Dermatol Surg* 1999;25:63-7.
36. MacFarlane DF, Pustelny BL, Goldberg LH. An assessment of the suitability of Mohs micrographic surgery in patients aged 90 years and older. *Dermatol Surg* 1997;23:389-93.
37. Mehrany K, Weenig RH, Pittelkow MR, Roenigk RK, Otley CC. High recurrence rates of basal cell carcinoma after Mohs surgery in patients with chronic lymphocytic leukemia. *Arch Dermatol* 2004;140:985-8.
38. Mohs FE, Zitelli JA. Microscopically controlled surgery in the treatment of carcinoma of the scalp. *Arch Dermatol* 1981; 117:764-9.
39. Mohs FE. Chemosurgical treatment of cancer of the extremities and trunk; a microscopically controlled method of excision. *Arch Surg* 1948;57:818-32.
40. Mohs FE. Micrographic surgery for the microscopically controlled excision of eyelid cancers. *Arch Ophthalmol* 1986;104: 901-9.
41. Murphy ME, Brodland DG, Zitelli JA. Definitive surgical treatment of 24 skin cancers not cured by prior imiquimod therapy: a case series. *Dermatol Surg* 2008;34: 1258-63.
42. Niparko JK, Swanson NA, Baker SR, Telian SA, Sullivan MJ, Kemink JL. Local control of auricular, periauricular, and external canal cutaneous malignancies with Mohs surgery. *Laryngoscope* 1990;100:1047-51.
43. Orengo IF, Salasche SJ, Fewkes J, Khan J, Thornby J, Rubin F. Correlation of histologic subtypes of primary basal cell carcinoma and number of Mohs stages required to achieve a tumor-free plane. *J Am Acad Dermatol* 1997;37:395-7.
44. Oriba HA, Sandermann S, Kircik L, Snow SN. Basal cell carcinoma of the vermilion zone of the lower lip: a report of 3 cases. *Oral Oncol* 1998;34:309-12.
45. Oriba HA, Snow SN. Tumors of the nasal columella treated by Mohs micrographic surgery. *Laryngoscope* 1997;107: 1647-50.
46. Osguthorpe JD, Abel CG, Lang P, Hochman M. Neurotropic cutaneous tumors of the head and neck. *Arch Otolaryngol Head Neck Surg* 1997;123:871-6.
47. Ratner D, Lowe L, Johnson TM, Fader DJ. Perineural spread of basal cell carcinomas treated with Mohs micrographic surgery. *Cancer* 2000;88:1605-13.
48. Riefkohl R, Pollack S, Georgiade GS. A rationale for the treatment of difficult basal cell and squamous cell carcinomas of the skin. *Ann Plast Surg* 1985;15:99-104.
49. Robins P, Nix M. Analysis of persistent disease on the ear following Mohs surgery. *Head Neck Surg* 1984;6:998-1006.
50. Robins P, Rodriguez-Sains R, Rabinovitz H, Rigel D. Mohs surgery for periocular basal cell carcinomas. *J Dermatol Surg Oncol* 1985;11:1203-7.
51. Robinson JK, Fisher SG. Recurrent basal cell carcinoma after incomplete resection. *Arch Dermatol* 2000;136:1318-24.
52. Sahl W, Yessenow R, Brou J, Levine N. Mohs' micrographic surgery and prompt reconstruction for basal cell carcinoma: report of 62 cases using the combined method. *J Okla State Med Assoc* 1994;87:10-5.
53. Sambandan PG, Goldman GD. Infiltrative basal cell carcinomas presenting as actinic keratosis: implications for clinical practice. *Dermatol Surg* 2008;34:9-14.
54. Shindel AW, Mann MW, Lev RY, Sengelmann R, Petersen J, Hruza GJ, et al. Mohs micrographic surgery for penile cancer: management and long-term followup. *J Urol* 2007;178:1980-5.
55. Siegle RJ, MacMillan J, Pollack SV. Infiltrative basal cell carcinoma: a nonsclerosing subtype. *J Dermatol Surg Oncol* 1986;12:830-6.
56. Smith SP, Grande DJ. Basal cell carcinoma recurring after radiotherapy: a unique, difficult treatment subclass of recurrent basal cell carcinoma. *J Dermatol Surg Oncol* 1991;17:26-30.
57. Tschen JP, Cohen PR, Schulze KE, Tschen JA, Nelson BR. Pleomorphic basal cell carcinoma: case reports and review. *South Med J* 2006;99:296-302.
58. Miller PK, Roenigk RK, Brodland DG, Randle HW. Cutaneous micrographic surgery: Mohs procedure. *Mayo Clin Proc* 1992; 67:971-80.
59. Alam M, Caldwell JB, Eliezri YD. Human papillomavirus-associated digital squamous cell carcinoma: literature review and report of 21 new cases. *J Am Acad Dermatol* 2003;48: 385-93.
60. Albom AJ. Squamous-cell carcinoma of the finger and nail bed: a review of the literature and treatment by the Mohs' surgical technique. *J Dermatol Surg* 1975;1:43-8.
61. Brodland DG, Zitelli JA. Surgical margins for excision of primary cutaneous squamous cell carcinoma. *J Am Acad Dermatol* 1992;27:241-8.
62. Brown MD, Zachary CB, Grekin RC, Swanson NA. Penile tumors: their management by Mohs micrographic surgery. *J Dermatol Surg Oncol* 1987;13:1163-7.
63. Chren MM, Torres JS, Stuart SE, Bertenthal D, Labrador RJ, Boscardin WJ. Recurrence after treatment of nonmelanoma skin cancer: a prospective cohort study. *Arch Dermatol* 2011; 147:540-6.
64. Chu A, Osguthorpe JD. Nonmelanoma cutaneous malignancy with regional metastasis. *Otolaryngol Head Neck Surg* 2003; 128:663-73.
65. Davidson TM, Haghghi P, Astarita R, Baird S, Seagren S. MOHS for head and neck mucosal cancer: report on 111 patients. *Laryngoscope* 1988;98:1078-83.
66. Dinehart SM, Pollack SV. Metastases from squamous cell carcinoma of the skin and lip: an analysis of twenty-seven cases. *J Am Acad Dermatol* 1989;21:241-8.
67. Dudley C, Kircik LH, Bullen R, Snow S, Landeck A, Buchler D. Vulvar squamous cell carcinoma metastatic to the skin. *Dermatol Surg* 1998;24:889-92.
68. Dzubow LM, Rigel DS, Robins P. Risk factors for local recurrence of primary cutaneous squamous cell carcinomas: treatment by microscopically controlled excision. *Arch Dermatol* 1982;118:900-2.
69. Fu JM, McCalmont T, Yu SS. Adenosquamous carcinoma of the skin: a case series. *Arch Dermatol* 2009;145:1152-8.
70. Goldberg LH, Silapunt S, Beyrau KK, Peterson SR, Friedman PM, Alam M. Keratoacanthoma as a postoperative complication of skin cancer excision. *J Am Acad Dermatol* 2004;50: 753-8.
71. Goldminz D, Bennett RG. Mohs micrographic surgery of the nail unit. *J Dermatol Surg Oncol* 1992;18:721-6.
72. Hansen JP, Drake AL, Walling HW. Bowen's disease: a four-year retrospective review of epidemiology and treatment at a university center. *Dermatol Surg* 2008;34:878-83.
73. Holmkvist KA, Roenigk RK. Squamous cell carcinoma of the lip treated with Mohs micrographic surgery: outcome at 5 years. *J Am Acad Dermatol* 1998;38:960-6.

74. Lang PG Jr, Braun MA, Kwatra R. Aggressive squamous carcinomas of the scalp. *Dermatol Surg* 2006;32:1163-70.
75. Larson PO. Keratoacanthomas treated with Mohs' micrographic surgery (chemosurgery): a review of forty-three cases. *J Am Acad Dermatol* 1987;16:1040-4.
76. Lawrence N, Cottel WI. Squamous cell carcinoma of skin with perineural invasion. *J Am Acad Dermatol* 1994;31:30-3.
77. Mayron R, Grimwood RE, Siegle RJ, Camisa C. Verrucous carcinoma arising in ulcerative lichen planus of the soles. *J Dermatol Surg Oncol* 1988;14:547-51.
78. Mehregan DA, Roenigk RK. Management of superficial squamous cell carcinoma of the lip with Mohs micrographic surgery. *Cancer* 1990;66:463-8.
79. Mikhail GR. Subungual epidermoid carcinoma. *J Am Acad Dermatol* 1984;11:291-8.
80. Mohs FE, Sahl WJ. Chemosurgery for verrucous carcinoma. *J Dermatol Surg Oncol* 1979;5:302-6.
81. Mohs FE, Snow SN. Microscopically controlled surgical treatment for squamous cell carcinoma of the lower lip. *Surg Gynecol Obstet* 1985;160:37-41.
82. Mohs FE, Snow SN, Messing EM, Kuglitsch ME. Microscopically controlled surgery in the treatment of carcinoma of the penis. *J Urol* 1985;133:961-6.
83. Mora RG. Microscopically controlled surgery (Mohs' chemosurgery) for treatment of verrucous squamous cell carcinoma of the foot (epithelioma cuniculatum). *J Am Acad Dermatol* 1983;8:354-62.
84. Padilla RS, Bailin PL, Howard WR, Dinner MI. Verrucous carcinoma of the skin and its management by Mohs' surgery. *Plast Reconstr Surg* 1984;73:442-7.
85. Peterson SR, Layton EG, Joseph AK. Squamous cell carcinoma of the nail unit with evidence of bony involvement: a multidisciplinary approach to resection and reconstruction. *Dermatol Surg* 2004;30:218-21.
86. Pugliano-Mauro M, Goldman G. Mohs surgery is effective for high-risk cutaneous squamous cell carcinoma. *Dermatol Surg* 2010;36:1544-53.
87. Robins P, Dzubow LM, Rigel DS. Squamous-cell carcinoma treated by Mohs' surgery: an experience with 414 cases in a period of 15 years. *J Dermatol Surg Oncol* 1981;7:800-1.
88. Sau P, McMarlin SL, Sperling LC, Katz R. Bowen's disease of the nail bed and periungual area: a clinicopathologic analysis of seven cases. *Arch Dermatol* 1994;130:204-9.
89. Silapunt S, Peterson SR, Goldberg LH. Squamous cell carcinoma of the auricle and Mohs micrographic surgery. *Dermatol Surg* 2005;31:1423-7.
90. Swanson NA, Taylor WB. Plantar verrucous carcinoma. Literature review and treatment by the Mohs' chemosurgery technique. *Arch Dermatol* 1980;116:794-7.
91. Thomas CJ, Wood GC, Marks VJ. Mohs micrographic surgery in the treatment of rare aggressive cutaneous tumors: the Geisinger experience. *Dermatol Surg* 2007;33:333-9.
92. Vergilis-Kalner IJ, Kriseman Y, Goldberg LH. Keratoacanthomas: overview and comparison between Houston and Minneapolis experiences. *J Drugs Dermatol* 2010;9:117-21.
93. Weber P, Rabinovitz H, Garland L. Verrucous carcinoma in penile lichen sclerosus et atrophicus. *J Dermatol Surg Oncol* 1987;13:529-32.
94. Goldberg LH, Chang JR, Baer SC, Schmidt JD. Proliferative actinic keratosis: three representative cases. *Dermatol Surg* 2000;26:65-9.
95. Goldberg LH, Joseph AK, Tschen JA. Proliferative actinic keratosis. *Int J Dermatol* 1994;33:341-5.
96. Goldberg LH, Kimyai-Asadi A. Diffuse epidermal and periadnexal squamous cell carcinoma in situ: a report of 13 patients. *J Am Acad Dermatol* 2005;53:623-7.
97. Albertini JG, Elston DM, Libow LF, Smith SB, Farley MF. Mohs micrographic surgery for melanoma: a case series, a comparative study of immunostains, an informative case report, and a unique mapping technique. *Dermatol Surg* 2002;28:656-65.
98. Bene NI, Healy C, Coldiron BM. Mohs micrographic surgery is accurate 95.1% of the time for melanoma in situ: a prospective study of 167 cases. *Dermatol Surg* 2008;34:660-4.
99. Bhardwaj SS, Tope WD, Lee PK. Mohs micrographic surgery for lentigo maligna and lentigo maligna melanoma using Mel-5 immunostaining: University of Minnesota experience. *Dermatol Surg* 2006;32:690-7.
100. Bricca GM, Brodland DG, Ren D, Zitelli JA. Cutaneous head and neck melanoma treated with Mohs micrographic surgery. *J Am Acad Dermatol* 2005;52:92-100.
101. Brodland DG. The treatment of nail apparatus melanoma with Mohs micrographic surgery. *Dermatol Surg* 2001;27:269-73.
102. Brown CD, Zitelli JA. The prognosis and treatment of true local cutaneous recurrent malignant melanoma. *Dermatol Surg* 1995;21:285-90.
103. Clayton BD, Leshin B, Hitchcock MG, Marks M, White WL. Utility of rush paraffin-embedded tangential sections in the management of cutaneous neoplasms. *Dermatol Surg* 2000;26:671-8.
104. Cohen LM, McCall MW, Hodge SJ, Freedman JD, Callen JP, Zax RH. Successful treatment of lentigo maligna and lentigo maligna melanoma with Mohs' micrographic surgery aided by rush permanent sections. *Cancer* 1994;73:2964-70.
105. Cohen LM, McCall MW, Zax RH. Mohs micrographic surgery for lentigo maligna and lentigo maligna melanoma: a follow-up study. *Dermatol Surg* 1998;24:673-7.
106. Hutcheson AC, McGowan JW IV, Maize JC Jr, Cook J. Multiple primary acral melanomas in African-Americans: a case series and review of the literature. *Dermatol Surg* 2007;33:1-10.
107. Katz TM, Silapunt S, Goldberg LH, Jih MH, Kimyai-Asadi A. Analysis of 197 female scalp tumors treated with Mohs micrographic surgery. *J Am Acad Dermatol* 2005;52:291-4.
108. Kimyai-Asadi A, Katz T, Goldberg LH, Ayala GB, Wang SQ, Vujevich JJ, et al. Margin involvement after the excision of melanoma in situ: the need for complete en face examination of the surgical margins. *Dermatol Surg* 2007;33:1434-41.
109. Mahoney EJ, Dolan RW, Choi EE, Olbricht SM. Surgical reconstruction of lentigo maligna defects. *Arch Facial Plast Surg* 2005;7:342-6.
110. Robinson JK. Margin control for lentigo maligna. *J Am Acad Dermatol* 1994;31:79-85.
111. Shumaker PR, Kelley B, Swann MH, Greenway HT Jr. Modified Mohs micrographic surgery for periocular melanoma and melanoma in situ: long-term experience at Scripps Clinic. *Dermatol Surg* 2009;35:1263-70.
112. Walling HW, Scupham RK, Bean AK, Ceilley RI. Staged excision versus Mohs micrographic surgery for lentigo maligna and lentigo maligna melanoma. *J Am Acad Dermatol* 2007;57:659-64.
113. Zalla MJ, Lim KK, Dicaudo DJ, Gagnot MM. Mohs micrographic excision of melanoma using immunostains. *Dermatol Surg* 2000;26:771-84.
114. Zitelli JA, Brown C, Hanusa BH. Mohs micrographic surgery for the treatment of primary cutaneous melanoma. *J Am Acad Dermatol* 1997;37:236-45.

115. Zitelli JA, Brown CD, Hanusa BH. Surgical margins for excision of primary cutaneous melanoma. *J Am Acad Dermatol* 1997; 37:422-9.
116. Zitelli JA, Mohs FE, Larson P, Snow S. Mohs micrographic surgery for melanoma. *Dermatol Clin* 1989;7:833-43.
117. Zitelli JA, Moy RL, Abell E. The reliability of frozen sections in the evaluation of surgical margins for melanoma. *J Am Acad Dermatol* 1991;24:102-6.
118. Dawes KW, Hanke CW. Dermatofibrosarcoma protuberans treated with Mohs micrographic surgery: cure rates and surgical margins. *Dermatol Surg* 1996;22:530-4.
119. DuBay D, Cimmino V, Lowe L, Johnson TM, Sondak VK. Low recurrence rate after surgery for dermatofibrosarcoma protuberans: a multidisciplinary approach from a single institution. *Cancer* 2004;100:1008-16.
120. Garcia C, Clark RE, Buchanan M. Dermatofibrosarcoma protuberans. *Int J Dermatol* 1996;35:867-71.
121. Gloster HM Jr, Harris KR, Roenigk RK. A comparison between Mohs micrographic surgery and wide surgical excision for the treatment of dermatofibrosarcoma protuberans. *J Am Acad Dermatol* 1996;35:82-7.
122. Hancox JG, Kelley B, Greenway HT Jr. Treatment of dermatofibroma sarcoma protuberans using modified Mohs micrographic surgery: no recurrences and smaller defects. *Dermatol Surg* 2008;34:780-4.
123. Haycox CL, Odland PB, Olbricht SM, Casey B. Dermatofibrosarcoma protuberans (DFSP): growth characteristics based on tumor modeling and a review of cases treated with Mohs micrographic surgery. *Ann Plast Surg* 1997;38: 246-51.
124. Hobbs ER, Wheeland RG, Bailin PL, Ratz JL, Yetman RJ, Zins JE. Treatment of dermatofibrosarcoma protuberans with Mohs micrographic surgery. *Ann Surg* 1988;207:102-7.
125. Huether MJ, Zitelli JA, Brodland DG. Mohs micrographic surgery for the treatment of spindle cell tumors of the skin. *J Am Acad Dermatol* 2001;44:656-9.
126. Loss L, Zeitouni NC. Management of scalp dermatofibrosarcoma protuberans. *Dermatol Surg* 2005;31:1428-33.
127. Love WE, Keiler SA, Tamburro JE, Honda K, Gosain AK, Bordeaux JS. Surgical management of congenital dermatofibrosarcoma protuberans. *J Am Acad Dermatol* 2009;61: 1014-23.
128. Meguerditchian AN, Wang J, Lema B, Kraybill WG, Zeitouni NC, Kane JM III. Wide excision or Mohs micrographic surgery for the treatment of primary dermatofibrosarcoma protuberans. *Am J Clin Oncol* 2009;33:300-3.
129. Nouri K, Lodha R, Jimenez G, Robins P. Mohs micrographic surgery for dermatofibrosarcoma protuberans: University of Miami and NYU experience. *Dermatol Surg* 2002;28:1060-4.
130. Parker TL, Zitelli JA. Surgical margins for excision of dermatofibrosarcoma protuberans. *J Am Acad Dermatol* 1995;32:233-6.
131. Ratner D, Thomas CO, Johnson TM, Sondak VK, Hamilton TA, Nelson BR, et al. Mohs micrographic surgery for the treatment of dermatofibrosarcoma protuberans: results of a multiinstitutional series with an analysis of the extent of microscopic spread. *J Am Acad Dermatol* 1997;37:600-13.
132. Robinson JK. Dermatofibrosarcoma protuberans resected by Mohs' surgery (chemosurgery): a 5-year prospective study. *J Am Acad Dermatol* 1985;12:1093-8.
133. Snow SN, Gordon EM, Larson PO, Bagheri MM, Bentz ML, Sable DB. Dermatofibrosarcoma protuberans: a report on 29 patients treated by Mohs micrographic surgery with long-term follow-up and review of the literature. *Cancer* 2004;101:28-38.
134. Thornton SL, Reid J, Papay FA, Vidimos AT. Childhood dermatofibrosarcoma protuberans: role of preoperative imaging. *J Am Acad Dermatol* 2005;53:76-83.
135. Tom WD, Hybarger CP, Rasgon BM. Dermatofibrosarcoma protuberans of the head and neck: treatment with Mohs surgery using inverted horizontal paraffin sections. *Laryngoscope* 2003;113:1289-93.
136. Abbate M, Zeitouni NC, Seyler M, Hicks W, Loree T, Cheney RT. Clinical course, risk factors, and treatment of microcystic adnexal carcinoma: a short series report. *Dermatol Surg* 2003; 29:1035-8.
137. Burns MK, Chen SP, Goldberg LH. Microcystic adnexal carcinoma: ten cases treated by Mohs micrographic surgery. *J Dermatol Surg Oncol* 1994;20:429-34.
138. Chiller K, Passaro D, Scheuller M, Singer M, McCalmont T, Grekin RC. Microcystic adnexal carcinoma: forty-eight cases, their treatment, and their outcome. *Arch Dermatol* 2000;136: 1355-9.
139. Friedman PM, Friedman RH, Jiang SB, Nouri K, Amonette R, Robins P. Microcystic adnexal carcinoma: collaborative series review and update. *J Am Acad Dermatol* 1999;41:225-31.
140. Hamm JC, Argenta LC, Swanson NA. Microcystic adnexal carcinoma: an unpredictable aggressive neoplasm. *Ann Plast Surg* 1987;19:173-80.
141. Khachemoune A, Olbricht SM, Johnson DS. Microcystic adnexal carcinoma: report of four cases treated with Mohs' micrographic surgical technique. *Int J Dermatol* 2005;44: 507-12.
142. LeBoit PE, Sexton M. Microcystic adnexal carcinoma of the skin: a reappraisal of the differentiation and differential diagnosis of an underrecognized neoplasm. *J Am Acad Dermatol* 1993;29:609-18.
143. Mayer MH, Winton GB, Smith AC, Lupton GP, Parry EL, Shagets FW. Microcystic adnexal carcinoma (sclerosing sweat duct carcinoma). *Plast Reconstr Surg* 1989;84: 970-5.
144. Snow S, Madjar DD, Hardy S, Bentz M, Lucarelli MJ, Bechard R, et al. Microcystic adnexal carcinoma: report of 13 cases and review of the literature. *Dermatol Surg* 2001;27:401-8.
145. Ang GC, Roenigk RK, Otley CC, Kim Phillips P, Weaver AL. More than 2 decades of treating atypical fibroxanthoma at Mayo Clinic: what have we learned from 91 patients? *Dermatol Surg* 2009;35:765-72.
146. Brown MD, Swanson NA. Treatment of malignant fibrous histiocytoma and atypical fibrous xanthomas with micrographic surgery. *J Dermatol Surg Oncol* 1989;15: 1287-92.
147. Davis JL, Randle HW, Zalla MJ, Roenigk RK, Brodland DG. A comparison of Mohs micrographic surgery and wide excision for the treatment of atypical fibroxanthoma. *Dermatol Surg* 1997;23:105-10.
148. Dzubow LM. Mohs surgery report: spindle cell fibrohistiocytic tumors: classification and pathophysiology. *J Dermatol Surg Oncol* 1988;14:490-5.
149. Jensen KJ, Peterson SR. Multiple recurrent atypical fibroxanthomas/superficial malignant fibrous histiocytomas of the forehead excised with Mohs micrographic surgery. *Dermatol Surg* 2006;32:588-91.
150. Limmer BL, Clark DP. Cutaneous micrographic surgery for atypical fibroxanthoma. *Dermatol Surg* 1997;23:553-8.
151. Seavolt M, McCall M. Atypical fibroxanthoma: review of the literature and summary of 13 patients treated with Mohs micrographic surgery. *Dermatol Surg* 2006;32:435-41.
152. Brissett AE, Olsen KD, Kasperbauer JL, Lewis JE, Goellner JR, Spotts BE, et al. Merkel cell carcinoma of the head and

- neck: a retrospective case series. *Head Neck* 2002;24:982-8.
153. Boyer JD, Zitelli JA, Brodland DG, D'Angelo G. Local control of primary Merkel cell carcinoma: review of 45 cases treated with Mohs micrographic surgery with and without adjuvant radiation. *J Am Acad Dermatol* 2002;47:885-92.
 154. Gollard R, Weber R, Kosty MP, Greenway HT, Massullo V, Humberson C. Merkel cell carcinoma: review of 22 cases with surgical, pathologic, and therapeutic considerations. *Cancer* 2000;88:1842-51.
 155. Hanke WC, Conner AC, Temofeew RK, Lingeman RE. Merkel cell carcinoma. *Arch Dermatol* 1989;125:1096-100.
 156. O'Connor WJ, Roenigk RK, Brodland DG. Merkel cell carcinoma: comparison of Mohs micrographic surgery and wide excision in eighty-six patients. *Dermatol Surg* 1997;23:929-33.
 157. Smith DE, Bielamowicz S, Kagan AR, Anderson PJ, Peddada AV. Cutaneous neuroendocrine (Merkel cell) carcinoma: a report of 35 cases. *Am J Clin Oncol* 1995;18:199-203.
 158. Snow SN, Larson PO, Hardy S, Bentz M, Madjar D, Landeck A, et al. Merkel cell carcinoma of the skin and mucosa: report of 12 cutaneous cases with 2 cases arising from the nasal mucosa. *Dermatol Surg* 2001;27:165-70.
 159. Bernstein SC, Roenigk RK. Leiomyosarcoma of the skin: treatment of 34 cases. *Dermatol Surg* 1996;22:631-5.
 160. Davidson LL, Frost ML, Hanke CW, Epinette WW. Primary leiomyosarcoma of the skin: case report and review of the literature. *J Am Acad Dermatol* 1989;21:1156-60.
 161. Iacobucci JJ, Stevenson TR, Swanson NA, Headington JT. Cutaneous leiomyosarcoma. *Ann Plast Surg* 1987;19:552-4.
 162. Starling J III, Coldiron BM. Mohs micrographic surgery for the treatment of cutaneous leiomyosarcoma. *J Am Acad Dermatol* 2011;64:1119-22.
 163. Folberg R, Whitaker DC, Tse DT, Nerad JA. Recurrent and residual sebaceous carcinoma after Mohs' excision of the primary lesion. *Am J Ophthalmol* 1987;103:817-23.
 164. Harvey JT, Anderson RL. The management of meibomian gland carcinoma. *Ophthalmic Surg* 1982;13:56-61.
 165. Ratz JL, Luu-Duong S, Kulwin DR. Sebaceous carcinoma of the eyelid treated with Mohs' surgery. *J Am Acad Dermatol* 1986;14:668-73.
 166. Snow SN, Larson PO, Lucarelli MJ, Lemke BN, Madjar DD. Sebaceous carcinoma of the eyelids treated by Mohs micrographic surgery: report of nine cases with review of the literature. *Dermatol Surg* 2002;28:623-31.
 167. Spencer JM, Nossa R, Tse DT, Sequeira M. Sebaceous carcinoma of the eyelid treated with Mohs micrographic surgery. *J Am Acad Dermatol* 2001;44:1004-9.
 168. Yount AB, Bylund D, Pratt SG, Greenway HT. Mohs micrographic excision of sebaceous carcinoma of the eyelids. *J Dermatol Surg Oncol* 1994;20:523-9.
 169. Coldiron BM, Goldsmith BA, Robinson JK. Surgical treatment of extramammary Paget's disease: a report of six cases and a reexamination of Mohs micrographic surgery compared with conventional surgical excision. *Cancer* 1991;67:933-8.
 170. Hendi A, Brodland DG, Zitelli JA. Extramammary Paget's disease: surgical treatment with Mohs micrographic surgery. *J Am Acad Dermatol* 2004;51:767-73.
 171. Mohs FE, Blanchard L. Microscopically controlled surgery for extramammary Paget's disease. *Arch Dermatol* 1979;115:706-8.
 172. O'Connor WJ, Lim KK, Zalla MJ, Gagnot M, Otley CC, Nguyen TH, et al. Comparison of Mohs micrographic surgery and wide excision for extramammary Paget's disease. *Dermatol Surg* 2003;29:723-7.
 173. Duffy MT, Harrison W, Sassoon J, Hornblase A. Sclerosing sweat duct carcinoma of the eyelid margin: unusual presentation of a rare tumor. *Ophthalmology* 1999;106:751-6.
 174. Durairaj VD, Hink EM, Kahook MY, Hawes MJ, Paniker PU, Esmaeli B. Mucinous eccrine adenocarcinoma of the periocular region. *Ophthalm Plast Reconstr Surg* 2006;22:30-5.
 175. Papalas JA, Proia AD. Primary mucinous carcinoma of the eyelid: a clinicopathologic and immunohistochemical study of 4 cases and an update on recurrence rates. *Arch Ophthalmol* 2010;128:1160-5.
 176. Weber PJ, Gretzula JC, Garland LD, Hevia O, Menn H. Syringoid eccrine carcinoma. *J Dermatol Surg Oncol* 1987;13:64-7.
 177. Weber PJ, Hevia O, Gretzula JC, Rabinovitz HC. Primary mucinous carcinoma. *J Dermatol Surg Oncol* 1988;14:170-2.
 178. Wildemore JK, Lee JB, Humphreys TR. Mohs surgery for malignant eccrine neoplasms. *Dermatol Surg* 2004;30:1574-9.
 179. Wittenberg GP, Robertson DB, Solomon AR, Washington CV. Eccrine porocarcinoma treated with Mohs micrographic surgery: a report of five cases. *Dermatol Surg* 1999;25:911-3.
 180. Yugueros P, Kane WJ, Goellner JR. Sweat gland carcinoma: a clinicopathologic analysis of an expanded series in a single institution. *Plast Reconstr Surg* 1998;102:705-10.
 181. Zhang Q, Wojno TH, Fitch SD, Grossniklaus HE. Mucinous eccrine adenocarcinoma of the eyelid: report of 6 cases. *Can J Ophthalmol* 2010;45:76-8.
 182. Behroozan DS, Goldberg LH, Glaich AS, Kaplan B, Kaye VN. Mohs micrographic surgery for deeply penetrating, expanding benign cutaneous neoplasms. *Dermatol Surg* 2006;32:958-65.
 183. Mamelak AJ, Goldberg LH, Katz TM, Graves JJ, Arnon O, Kimyai-Asadi A. Desmoplastic trichoepithelioma. *J Am Acad Dermatol* 2010;62:102-6.
 184. Bullen R, Larson PO, Landeck AE, Nychay S, Snow SN, Hazen P, et al. Angiosarcoma of the head and neck managed by a combination of multiple biopsies to determine tumor margin and radiation therapy: report of three cases and review of the literature. *Dermatol Surg* 1998;24:1105-10.
 185. Goldberg DJ, Kim YA. Angiosarcoma of the scalp treated with Mohs micrographic surgery. *J Dermatol Surg Oncol* 1993;19:156-8.
 186. Muscarella VA. Angiosarcoma treated by Mohs micrographic surgery. *J Dermatol Surg Oncol* 1993;19:1132-3.
 187. National Comprehensive Cancer Network. NCCN clinical practice guidelines in oncology: basal cell and squamous cell skin cancers. Available from: URL:<http://www.nccn.org>. Accessed March 1, 2011.
 188. Farasat S, Yu SS, Neel VA, Nehal KS, Lardaro T, Mihm MC, et al. A new American Joint Committee on Cancer staging system for cutaneous squamous cell carcinoma: creation and rationale for inclusion of tumor (T) characteristics. *J Am Acad Dermatol* 2011;64:1051-9.
 189. Center for Medicare and Medicaid Services. Local coverage determination (LCD) for Mohs micrographic surgery (MMS); L5337, L9666, L17882, L26371, L26733, L23735, L24331, L27503, L27580, L28278, L28932, L28953, L29230, L29366, L30713. Available from: URL:<http://www.cms.gov/medicare-coverage-database/>. Accessed March 1, 2011.
 190. Drake LA, Dinehart SM, Goltz RW, Graham GF, Hordinsky MK, Lewis CW, et al. Guidelines of care for Mohs micrographic surgery: American Academy of Dermatology. *J Am Acad Dermatol* 1995;33:271-8.
 191. Brook RH. The RAND/UCLA appropriateness method. In: McCormick KA, Moore SR, Siegl RA, editors. *Clinical practice*

- guideline development: methodology perspectives. Rockville (MD): Public Health Service: AHCR; 1994. pp. 59-70.
192. Patel MR, Spertus JA, Brindis RG, Hendel RC, Douglas PS, Peterson ED, et al. ACCF proposed method for evaluating the appropriateness of cardiovascular imaging. *J Am Coll Cardiol* 2005;46:1606-13.
 193. American College of Radiology. ACR appropriateness criteria; overview. Available from: URL:http://www.acr.org/SecondaryMainMenuCategories/quality_safety/app_criteria/overview.aspx. Accessed March 4, 2011.
 194. National Comprehensive Cancer Network. NCCN clinical practice guidelines in oncology; dermatofibrosarcoma protuberans. Available from: URL:<http://www.nccn.org>. Accessed March 1, 2011.
 195. National Comprehensive Cancer Network. NCCN clinical practice guidelines in oncology; Merkel cell carcinoma. Available from: URL:<http://www.nccn.org>. Accessed March 1, 2011.
 196. National Comprehensive Cancer Network. NCCN clinical practice guidelines in oncology; melanoma. Available from: URL:<http://www.nccn.org>. Accessed March 1, 2011.
 197. Bichakjian CK, Halpern AC, Johnson TM, Foote Hood A, Grichnik JM, Swetter SM, et al. Guidelines of care for the management of primary cutaneous melanoma: American Academy of Dermatology. *J Am Acad Dermatol* 2011;65:1032-47.
 198. Mudigonda T, Pearce DJ, Yentzer BA, Williford P, Feldman SR. The economic impact of non-melanoma skin cancer: a review. *J Natl Compr Canc Netw* 2010;8:888-96.
 199. Tierney EP, Hanke CW. Cost effectiveness of Mohs micrographic surgery: review of the literature. *J Drugs Dermatol* 2009;8:914-22.
 200. Rogers HW, Coldiron BM. A relative value unit-based cost comparison of treatment modalities for nonmelanoma skin cancer: effect of the loss of the Mohs multiple surgery reduction exemption. *J Am Acad Dermatol* 2009;61:96-103.
 201. Seidler AM, Bramlette TB, Washington CV, Szeto H, Chen SC. Mohs versus traditional surgical excision for facial and auricular nonmelanoma skin cancer: an analysis of cost-effectiveness. *Dermatol Surg* 2009;35:1776-87.
 202. Chen JG, Yelverton CB, Polissety SS, Housman TS, Williford PM, Teuschler HV, et al. Treatment patterns and cost of nonmelanoma skin cancer management. *Dermatol Surg* 2006;32:1266-71.
 203. Chen JG, Fleischer AB Jr, Smith ED, Kancler C, Goldman ND, Williford PM, et al. Cost of nonmelanoma skin cancer treatment in the United States. *Dermatol Surg* 2001;27:1035-8.
 204. Bialy TL, Whalen J, Veledar E, Lafreniere D, Spiro J, Chartier T, et al. Mohs micrographic surgery vs traditional surgical excision: a cost comparison analysis. *Arch Dermatol* 2004;140:736-42.
 205. Cook J, Zitelli JA. Mohs micrographic surgery: a cost analysis. *J Am Acad Dermatol* 1998;39:698-703.
 206. Geisse JK. Biopsy techniques for pigmented lesions of the skin. *Pathology (Phila)* 1994;2:181-93.
 207. Mehregan DR, Dooley VN. How to get the most out of your skin biopsies. *Int J Dermatol* 2007;46:727-33.
 208. Siddaraju N, Solo S, Badhe BA, Srinivasan R. Benign skin adnexal tumor vs hemangioma: diagnostic pitfall due to cytologic sampling error. *Acta Cytol* 2008;52:378-80.
 209. Stevens G, Cocherell CJ. Avoiding sampling error in the biopsy of pigmented lesions. *Arch Dermatol* 1996;132:1380-2.
 210. Voermans NC, Pillen S, de Jong EM, Creemers MC, Lammens M, van Alfen N. Morphea profunda presenting as a neuromuscular mimic. *J Clin Neuromuscul Dis* 2008;9:407-14.
 211. Chang TT, Somach SC, Wagamon K, Somani AK, Pomeranz J, Jaworsky C, et al. The inadequacy of punch-excised melanocytic lesions: sampling through the block for the determination of "margins." *J Am Acad Dermatol* 2009;60:990-3.
 212. Somach SC, Taira JW, Pitha JV, Everett MA. Pigmented lesions in actinically damaged skin: histopathologic comparison of biopsy and excisional specimens. *Arch Dermatol* 1996;132:1297-302.
 213. American Medical Association. Mohs Micrographic Surgery. *CPT Assistant* 2006;16:1-7